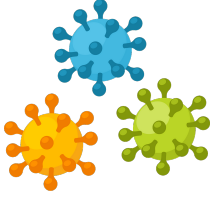




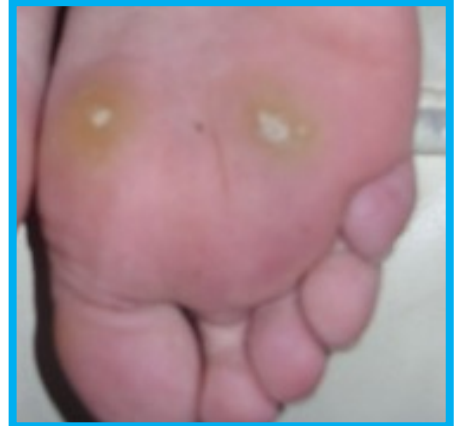PATHOGENESIS



- **Human Papillomavirus (HPV)** is the causative agent.
- HPV **infects the basal keratinocytes** in the epithelium.
- **Epithelial hyperplasia** leads to the classic appearance.
- Transmission through **skin-to-skin contact** and **surfaces**

CLINICAL PRESENTATION

- **Prevalence** peaks during **adolescence**.
- Appear as hyperkeratotic, exophytic papules.
- Commonly on **dorsal aspect of the hands/fingers** and **plantar surface of feet**.
- Can have **thrombosed capillaries** and **interruption of the skin lines**.



MANAGEMENT

- **Watchful waiting** (>75% of cases **self-resolve** by 2 years).

1 First line

- Salicylic acid
- Cryotherapy

2 Second line

- Cantharidin*

3 Third line

- Bleomycin
- Laser therapy
- Intralesional immunotherapy

* Can cause a circle of warts around the lesion called a donut wart.

PREVENTION

- ✓ Patients can spread the virus to an unaffected area of skin. Therefore, inform patients **not to touch their warts** and to groom the affected body part with different equipment to prevent further spread (e.g. do not share pumice stones with family members).
- ✓ HPV vaccine only prevents genital warts.